

PATIENT PRESENTING CLINICAL SIGNS

Remi Duerr
History: Littermate died suddenly
BP: 171/114, 67/50, 66/50, 51/20

SPECIES

Feline

ECHOCARDIOGRAPHIC FINDINGS

Multiple 2D, M-mode, and Doppler video loops and still images are submitted for review.

BREED

DSH

Left atrial size is normal. The mitral valve is normal. Left ventricular wall thickness is normal. Left ventricular internal dimensions are normal. Left ventricular systolic function is hyperdynamic. The aorta and aortic valve are normal. Right atrial and right ventricular dimensions are normal. The tricuspid valve is normal. The pulmonary artery and pulmonic valve are normal. No shunting lesions are visualized. No heartworms are visualized. No pericardial effusion or cardiac masses are seen.

SEX

FS

LA/Ao - 1.23

IVSd - 4.2 mm

AGE

LVPWd - 4.3 mm

LVIDd - 13.5 mm

2 years

LVIDs - 6.0 mm

FS - 55.5%

WEIGHT

LVOT - 1.05 m/s

RVOT - 0.98 m/s

5 lbs

ELECTROCARDIOGRAPHIC FINDINGS

INTERPRETED BY

A single lead ECG is submitted for review.

Keith Blass, DVM,
MS, DACVIM

HR: 220 bpm

Rhythm: Sinus

IMAGING PERFORMED BY

Sinus tachycardia is present in this recording. All complex amplitudes and intervals are within normal limits. No premature beats or conduction blocks are seen.

Rebekah Jakum, CVT
ARDMS/RVT

ASSESSMENT/RECOMMENDATIONS

Normal echocardiogram and ECG

HOSPITAL NAME

Conrad Weiser AH

These examinations demonstrate no abnormalities. As such, no potential reason for an increased risk for sudden death is appreciated in these exams.

No therapy is recommended based on these exams.

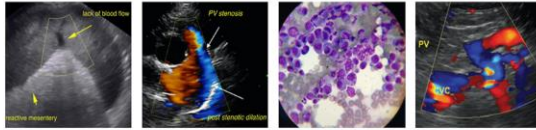
REFERRING VET

Dr. Comalli

A recheck echocardiogram is recommended if new physical exam and/or clinical abnormalities suggestive of cardiac dysfunction develop.

DATE

9.17.2021



PATIENT

Remi Duerr

SPECIES

Feline

BREED

DSH

SEX

FS

AGE

2 years

WEIGHT

5 lbs

INTERPRETED BY

Keith Blass, DVM,
MS, DACVIM

IMAGING PERFORMED BY

Rebekah Jakum, CVT
ARDMS/RVT

HOSPITAL NAME

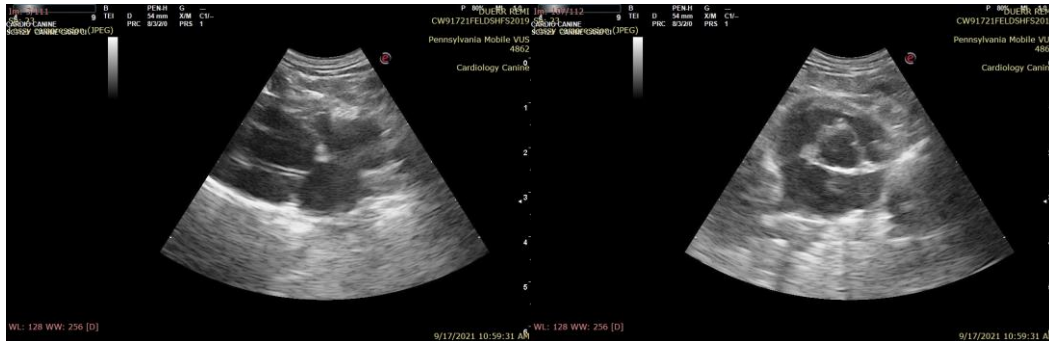Conrad Weiser AH

REFERRING VET

Dr. Comalli

DATE

9.17.2021



SEX The information and recommendations provided are based on the images presented by the referring veterinarian. No evaluation can be communicated regarding pathology that was not visible in the image/video clips provided.

AGE Thank you for this referral. If the clinical or image interpretation does not parallel your findings or if I can be of any further assistance please contact me.

WEIGHT Keith Blass, DVM, MS, DACVIM (Cardiology)
KeithBlass@gmail.com
631-804-5754